

Acland's Video Atlas of Human Anatomy



Wolters Kluwer
Health

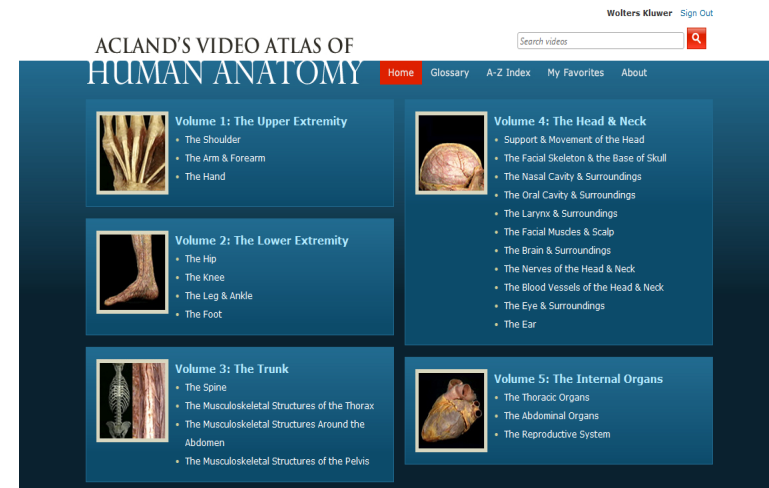
ACLAND'S VIDEO ATLAS OF
HUMAN ANATOMY

人體實體解剖影片資料庫

內容分五大類：

1. 上肢 (The Upper Extremity)
2. 下肢 (The Lower Extremity)
3. 軀幹 (The Trunk)
4. 頭部與頸部 (The Head & Neck)
5. 身體器官 (The Internal Organs)

每大類再細分相關部位。可藉由
瀏覽, 快速查詢功能, 或AtoZ分類方式
找尋所需的影片



ACLAND'S VIDEO ATLAS OF HUMAN ANATOMY

Search videos



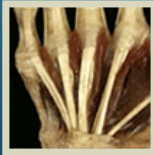Home

Glossary

A-Z Index

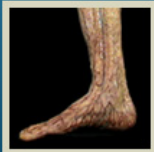My Favorites

About



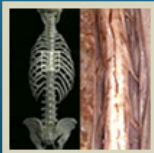Volume 1: The Upper Extremity

- The Shoulder
- The Arm & Forearm
- The Hand



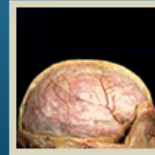
Volume 2: The Lower Extremity

- The Hip
- The Knee
- The Leg & Ankle
- The Foot



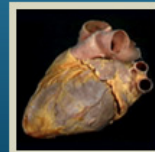
Volume 3: The Trunk

- **The Spine**
- The Musculoskeletal Structures of the Thorax
- The Musculoskeletal Structures Around the Abdomen
- The Musculoskeletal Structures of the Pelvis



Volume 4: The Head & Neck

- Support & Movement of the Head
- The Facial Skeleton & the Base of Skull
- The Nasal Cavity & Surroundings
- The Oral Cavity & Surroundings
- The Larynx & Surroundings
- The Facial Muscles & Scalp
- The Brain & Surroundings
- The Nerves of the Head & Neck
- The Blood Vessels of the Head & Neck
- The Eye & Surroundings
- The Ear



Volume 5: The Internal Organs

- The Thoracic Organs
- The Abdominal Organs
- The Reproductive System



ACLAND'S VIDEO ATLAS OF HUMAN ANATOMY

Search videos



Home Glossary A-Z Index My Favorites About



VOLUME 1
The Upper Extremity



VOLUME 2
The Lower Extremity



VOLUME 3
The Trunk



VOLUME 4
The Head & Neck



VOLUME 5
The Internal Organs

Volume 3

The Trunk

▼ The Spine

- 3.1.1 The vertebral column, features of a typical vertebra (4:45)
- 3.1.2 Cervical and thoracic vertebrae (5:01)
- 3.1.3 Lumbar vertebrae, sacrum (3:35)
- 3.1.4 Ligaments of the vertebral column, intervertebral disks (4:41)
- 3.1.5 Intervertebral joints (0:47)
- 3.1.6 Review of bones, joints, and ligaments of the vertebral column (1:45)
- 3.1.7 Paravertebral muscles (4:54)
- 3.1.8 Spinal cord (cross section), spinal meninges, dural sac (3:16)
- 3.1.9 Spinal cord (from behind), nerve roots (4:22)
- 3.1.10 Review of paravertebral muscles and spinal cord (1:20)

▶ The Musculoskeletal Structures of the Thorax

▶ The Musculoskeletal Structures Around the Abdomen

▶ The Musculoskeletal Structures of the Pelvis



Acland's Video Atlas of Human Anatomy




Wolters Kluwer Sign Out

ACLAND'S VIDEO ATLAS OF HUMAN ANATOMY

Search videos 

Home Glossary A-Z Index My Favorites About

Volume 3: The Trunk > The Spine

 PDF Transcript  Email  Add to Favorites

3.1.9. Spinal cord (from behind), nerve roots (4:22)

JUMP TO

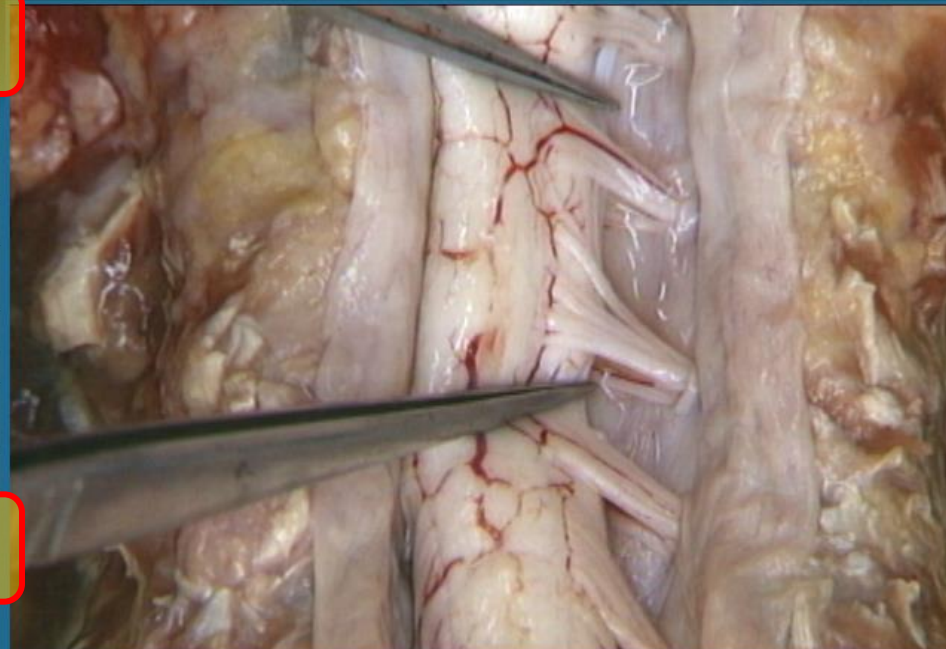
可隨意跳到影片中的片段

- Spinal nerve roots
- Denticulate ligaments
- Spinal nerve filaments, posterior view
- Spinal nerves: obliquity
- Cauda equina
- Spinal nerves: emergence from intervertebral foramen
- Dura around emerging spinal nerve
- Dorsal root ganglion
- Anterior primary ramus; Posterior primary ramus
- Numbering of spinal nerves

SEE ALSO

可點選觀看其他相關的影片

- dura
- spinal nerves
- spinal cord
- vertebral column
- cervical spinal nerve
- intervertebral foramen
- dura, spinal
- spinal nerves, filaments



00:00 04:22
 PLAY   MENU

◀ PREVIOUS 3.1.8 Spinal cord (cross section), spinal meninges, dural sac

3.1.10 Review of paravertebral muscles and spinal cord NEXT ▶



Wolters Kluwer
Health

ACLAND'S VIDEO ATLAS OF HUMAN ANATOMY

Search videos



Home Glossary A-Z Index My Favorites About

Volume 3: The Trunk > The Spine

PDF Transcript

Email

Add to Favorites

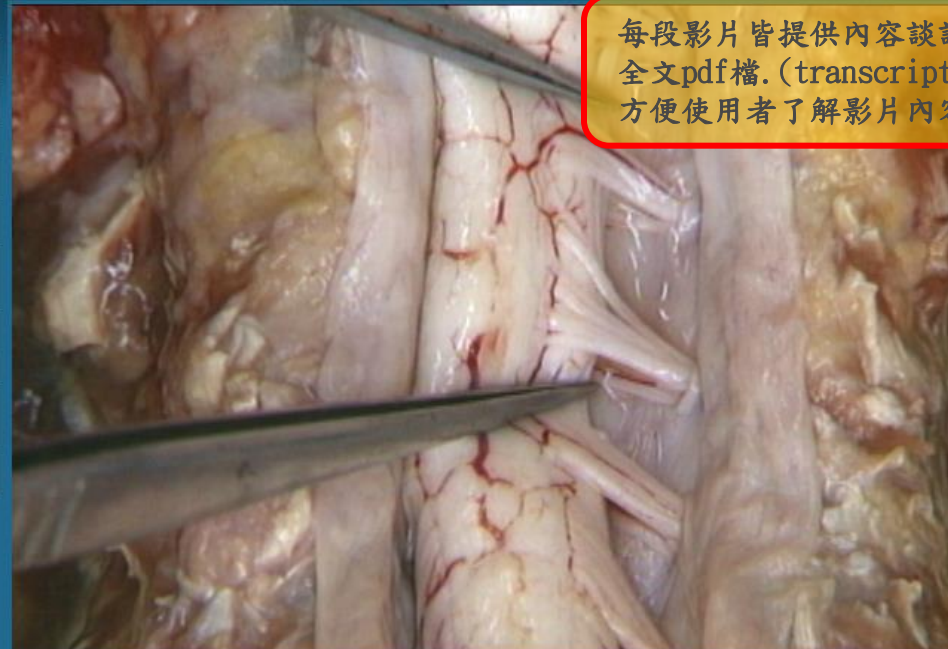
3.1.9. Spinal cord (from behind), nerve roots (4:22)

JUMP TO

- Spinal nerve roots
- Denticulate ligaments
- Spinal nerve filaments, posterior view
- Spinal nerves: obliquity
- Cauda equina
- Spinal nerves: emergence from intervertebral foramen
- Dura around emerging spinal nerve
- Dorsal root ganglion
- Anterior primary ramus; Posterior primary ramus
- Numbering of spinal nerves

SEE ALSO

- dura
- spinal nerves
- spinal cord
- vertebral column
- cervical spinal nerve
- intervertebral foramen
- dura, spinal
- spinal nerves, filaments



每段影片皆提供內容談話全文pdf檔。(transcript)方便使用者了解影片內容

00:00

04:22

PLAY



MENU

PREVIOUS 3.1.8 Spinal cord (cross section), spinal meninges, dural sac

3.1.10 Review of paravertebral muscles and spinal cord NEXT



3.1.9

Spinal cord (from behind), nerve roots (4.22)

Let's see some more details. These are nerve roots - we'll look at them in a minute. The cord is attached to the dura by a series of fine, triangular ligaments, the denticulate ligaments. To see how the spinal nerves arise, we'll go up to the cervical region. The denticulate ligaments have been divided.

Each spinal nerve arises from a small bundle of dorsal filaments, which unite to form the dorsal, sensory root of the nerve, and a similar bundle of ventral filaments, which unite to form the ventral, motor root.

In the cervical region, the nerve roots follow a slightly oblique, downward course. In the thoracic region their course becomes more oblique.

Here right at the lower end of the spinal cord, this continuous line of nerve filaments gives rise to a large number of nerve roots, which run vertically downward, almost hiding the very end of the cord, which is here




可儲存或列印

ACLAND'S VIDEO ATLAS OF HUMAN ANATOMY

Search videos 

Home Glossary A-Z Index My Favorites About

Volume 3: The Trunk > The Spine

 PDF Transcript  Email  Add to Favorites

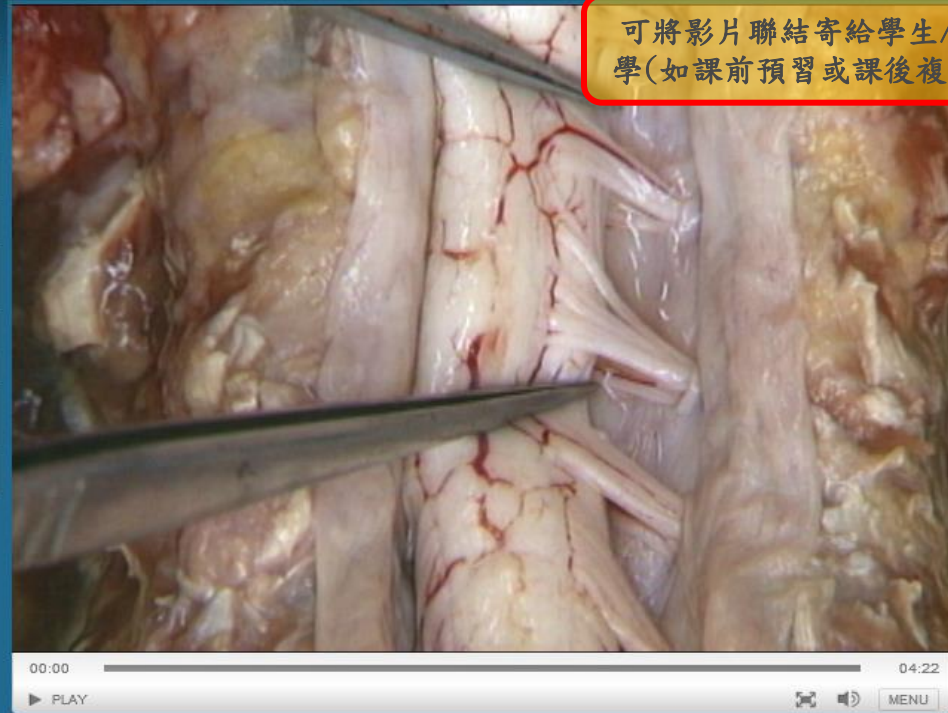3.1.9. Spinal cord (from behind), nerve roots (4:22)

JUMP TO

- Spinal nerve roots
- Denticulate ligaments
- Spinal nerve filaments, posterior view
- Spinal nerves: obliquity
- Cauda equina
- Spinal nerves: emergence from intervertebral foramen
- Dura around emerging spinal nerve
- Dorsal root ganglion
- Anterior primary ramus; Posterior primary ramus
- Numbering of spinal nerves

SEE ALSO

- dura
- spinal nerves
- spinal cord
- vertebral column
- cervical spinal nerve
- intervertebral foramen
- dura, spinal
- spinal nerves, filaments



◀ PREVIOUS 3.1.8 Spinal cord (cross section), spinal meninges, dural sac

3.1.10 Review of paravertebral muscles and spinal cord NEXT ▶



Acland's Video Atlas of Human Anatomy

Wolters Kluwer Sign Out

ACLAND'S HUMAN ANATOMY

Volume 3: The Trunk > The Spinal Cord

3.1.9. Spinal cord (from behind), nerve roots

JUMP TO

- Spinal nerve roots
- Denticulate ligaments
- Spinal nerve filaments, roots
- Spinal nerves: obliquity
- Cauda equina
- Spinal nerves: emergence
- Intervertebral foramen
- Dura around emerging spinal nerves
- Dorsal root ganglion
- Anterior primary ramus
- Posterior primary ramus
- Numbering of spinal nerves

Email a link to this video:

3.1.9 Spinal cord (from behind), nerve roots

We will email a link to your recipient(s) that is good for the next 3 days (and can be clicked on 10 times maximum).

Your name:

Your email:

Recipient's email:

Limited to 5 recipients. Separate multiple addresses with commas.

Message (optional)

收信人可在三天內, 最多點閱十次該影片(對方即使沒有訂購也可觀看)




輸入你的姓名, email, 對方的email(最多五個)及email內容(可不填寫)

ACLAND'S VIDEO ATLAS OF HUMAN ANATOMY

Search videos 

Home Glossary A-Z Index My Favorites About

Volume 3: The Trunk > The Spine

 PDF Transcript  Email  Add to Favorites

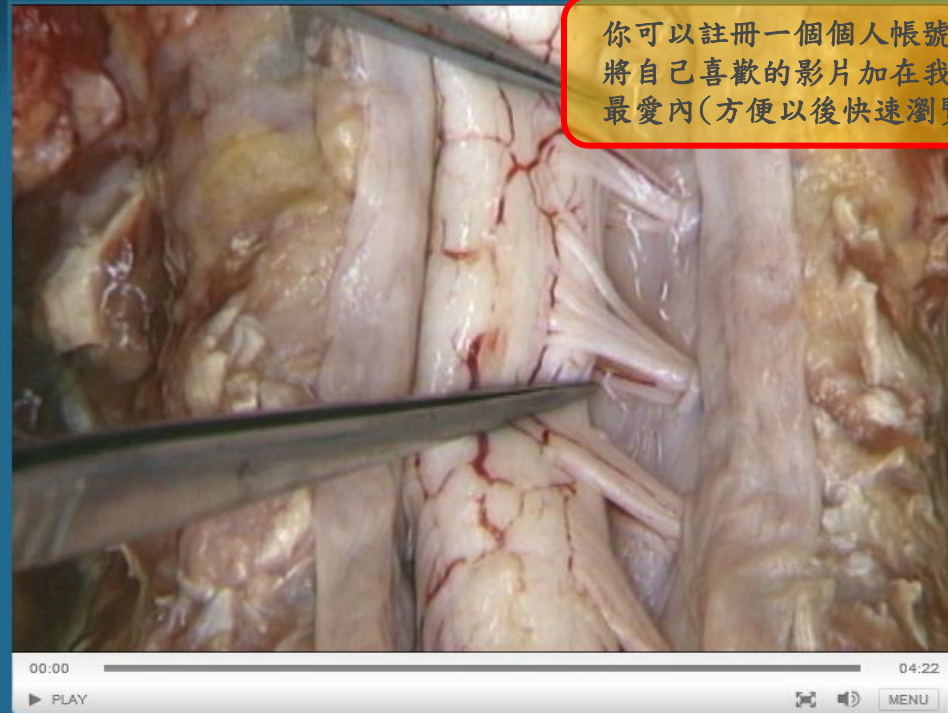3.1.9. Spinal cord (from behind), nerve roots (4:22)

JUMP TO

- Spinal nerve roots
- Denticulate ligaments
- Spinal nerve filaments, posterior view
- Spinal nerves: obliquity
- Cauda equina
- Spinal nerves: emergence from intervertebral foramen
- Dura around emerging spinal nerve
- Dorsal root ganglion
- Anterior primary ramus; Posterior primary ramus
- Numbering of spinal nerves

SEE ALSO

- dura
- spinal nerves
- spinal cord
- vertebral column
- cervical spinal nerve
- intervertebral foramen
- dura, spinal
- spinal nerves, filaments



◀ PREVIOUS 3.1.8 Spinal cord (cross section), spinal meninges, dural sac

3.1.10 Review of paravertebral muscles and spinal cord NEXT ▶

Acland's Video Atlas of Human Anatomy

Wolters Kluwer Sign Out

ACLAND'S VIDEO ATLAS OF HUMAN ANATOMY

Search videos



Home

Glossary

A-Z Index

My Favorites

About

Glossary

Many anatomic structures are still known by names given when Greek, Arabic and Latin were the languages of learning. There are no accepted translations for most anatomic names, so these interesting links with the past remain in service.

提供解剖相關的詞彙表

A B C D E F G H I J L M N O P Q R S T U V X Z

Abduct LATIN *ab*, away + *ducere*, pull.

Acetabulum LATIN *acteum*, vinegar + *abrum*, holder. Small cup for vinegar, hence any small cup.

Acromion GREEK *acron*, summit + *omos*, shoulder.

Adduct LATIN *ad*, towards + *ducere*, pull.

Adrenal LATIN *ad*, toward + *ren*, kidney.

Ala (alar) LATIN *ala*, wing.

Alveolus (alveolar) LATIN *alveolus*, small compartment.

Ampulla LATIN *ampulla*, flask.

Anconeus GREEK *ancone*, elbow.

Ansa LATIN *ansa*, handle.

Antecubital LATIN *ante*, in front: *cubitum*, elbow.



Acland's Video Atlas of Human Anatomy

Wolters Kluwer Sign Out

ACLAND'S VIDEO ATLAS OF HUMAN ANATOMY

Home Glossary **A-Z Index** My Favorites About

Search videos

A-Z Index

A B C D E F G H I J K L M N O P Q R S T U V W X Z

- abdomen
- abdominal arteries
- abdominal cavity
- abdominal cavity, empty
- abdominal cavity, introduction
- abdominal cavity, upper and lower extent
- abdominal muscles
- abdominal veins
- abducent nerve
- abducent nerve, and cavernous sinus
- abducent nerve, dural opening
- abducent nerve, emergence from medulla
- anterior scalene muscle, and superior thoracic aperture
- anterior superior alveolar nerves
- anterior superior iliac spine
- anterior tibial artery
- anterior tibial artery, at ankle
- anterior tibial artery, origin
- antihelix
- antitragus
- anular ligament
- anular ligament, alone
- anular ligament, in intact elbow joint
- anulus fibrosus

Annotations:

- 或可輸入關鍵字來搜尋 (Red box pointing to search bar)
- 可採用AtoZ方式查詢所需的影片資料 (Red box pointing to A-Z Index)

Q & A

如有產品相關問題, 請隨時與我聯繫

孟家瑋, Email: gary.man@wolterskluwer.com

ACLAND'S VIDEO ATLAS OF
HUMAN ANATOMY

